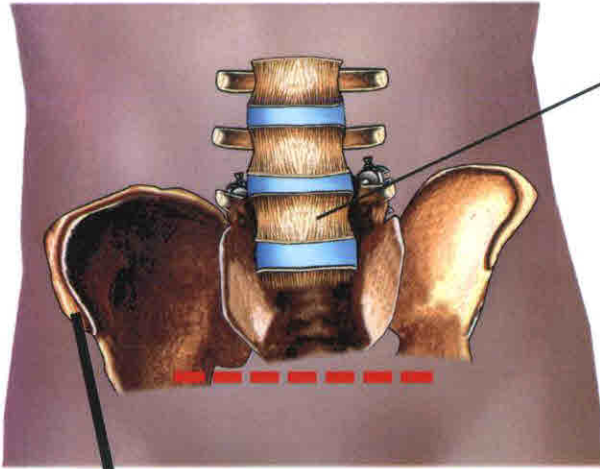


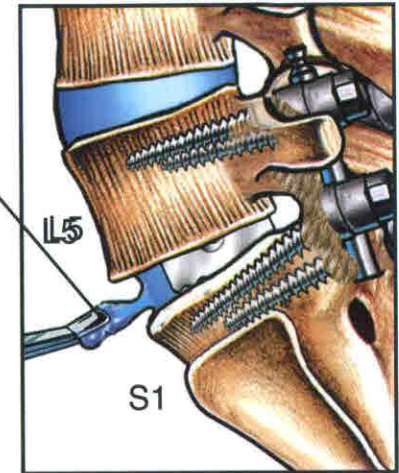
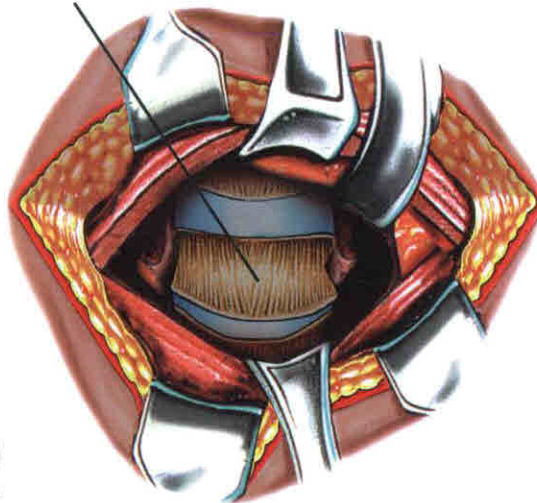
ANTERIOR LUMBAR DISCECTOMY & FUSION, 3/31/14

A. INCISION TO EXPOSE LUMBAR SPINE

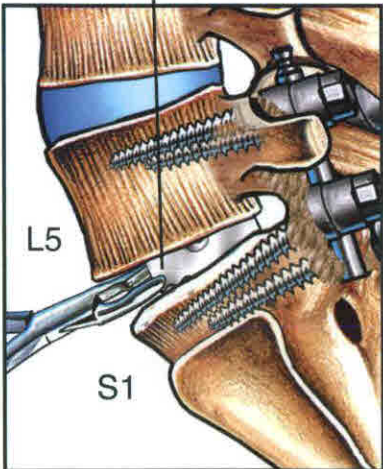


BONE GRAFT HARVESTED FROM RIGHT ILIAC CREST

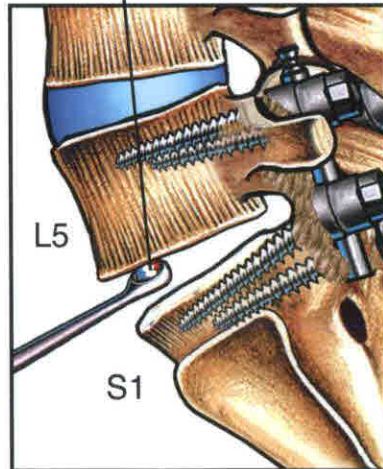
B. L5-S1 DISCECTOMY



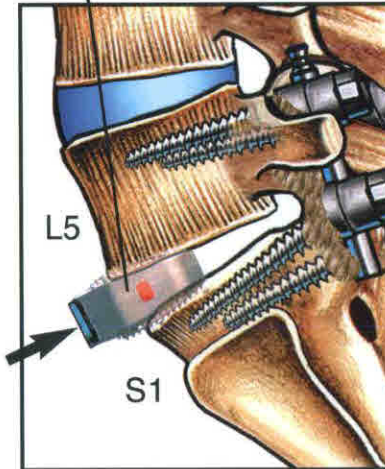
C. REMOVAL OF OLD CAGE IN PIECEMEAL FASHION



D. SCRAPING OF END PLATES



E. PLACEMENT OF BONE GRAFT FILLED CAGE



F. PLACEMENT OF PLATE & SCREWS

